

# Interventional Regenerative Orthopedic Medicine (IROM): A Primary Care Physicians Guide To Understanding This New Discipline.



**MICHAEL N. BROWN, MD**

**Interventional Regenerative Orthopedic Medicine Institute**

*Physical Medicine & Rehabilitation  
Interventional Pain Management*

WASHINGTON OFFICE  
1515 116<sup>th</sup> Avenue NE, Suite #202  
Bellevue, WA 98004

CALIFORNIA OFFICE  
10 Harris Court, Bldg A, Suite #1  
Monterey, CA 93940

**Office#: 425.326.1665    Fax#: 425.326.1667**

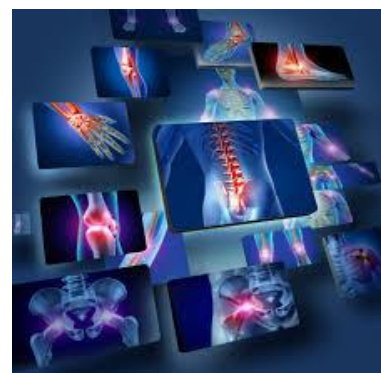
## **INTRODUCTION:**

The IROM organization represents six centers across the United States that are overseen by a consortium of physicians, engineers and PhD scientists collaborating to develop regenerative medicine science and technology. We conduct basic science research and multicenter clinical trials on primarily orthopedic application of our stem cell, tissue engineering and regenerative medicine techniques. This organization is also in the process of developing consensus guidelines to govern the manner in which these institutes evaluate and treat specific orthopedic disease entities.

Physicians practicing in this area are specialized in interventional, non-operative, minimally invasive orthopedic procedures and some have coined the term Interventional Orthopedic Medicine to distinguish these providers from orthopedic surgery specialists. Typically, these physicians are not orthopedic surgeons but rather interventional spine specialists with subspecialty pain medicine training as we will expound upon in this discussion. A new “hybrid” medical subspecialty has been emerging which we reference as “Interventional Regenerative Orthopedic Medicine.” In this discussion we will review why there is a need for such distinction and what services, procedures and scope of practice these practitioners are currently working in. We will also review a number of case studies to provide examples of the techniques and methods used by our institutes and providers.

## **THE NEED FOR INTEVENTIONAL ORTHOPEDIC & RENGENERATIVE OTHOPEDIC MEDICINE:**

Hip and knee pain associated with osteoarthritis a common source of chronic pain in older adults.<sup>1</sup> Prevalence of hip osteoarthritis ranges from 0.4% to 27%<sup>2-4</sup> Osteoarthritis (OA) of the knee is more common than the hip.<sup>5</sup> According to the Agency for Healthcare Research and Quality more than 600,000 knee replacements and 285,000 total hip replacements are performed each year in the US. The demand for repeat joint replacement or revision of the previous joint replacement will double in the next 10 years. As the demand for joint replacement surgery increases, the supply of orthopedic surgeons performing these procedures are on the decline which may lead to a demand crisis.<sup>6</sup>



Those seeking alternatives to chronic back and neck pain is also on the rise. The escalating cost of chronic back pain for example in the baby boomer population is staggering. In 2006 through 2007 the cost of treating the baby boomers with low back pain soared 129% from \$15.6 billion in 2000-2001-35.7 billion in 2006-2007.<sup>7</sup> The reason for this was estimated to be secondary to simply the “aging spine.”<sup>7</sup> Primary care physicians are inundated with countless patients in chronic pain who are failing basic conservative management but are not considered candidate for surgical procedure. These individuals often “fall through the cracks” and find themselves seeking alternatives to treatment. These patients find themselves caught in a seemingly “endless maze” of treatment options and yet continue to fail. Despite the complexity of spine pain and spine disorders, we believe the physicians specially trained in IROM have a unique skill set for both diagnosis and management of this patient population.

The primary care physician’s role in the future is going to continue to remain critically important. With reimbursement for services shrinking and the time demands with new healthcare regulations eating away at the time we once used to actually care for patients, the primary care physician is placed in a difficult position trying to sort out what to do with these difficult patients. To have a physician who is trained to manage the patient who seeks your care that is not responding to physical therapy and conservative care can be invaluable. It is even more valuable if the physician specialist specializes in “nonoperative” management. Finding a superb orthopedic surgeon is not difficult. Finding a physician who has the subspecialty of advanced musculoskeletal and spine management, who is an IROM expert is like finding a “needle and haystack.” The IROM practitioner can provide early intervention and save cost, time, morbidity and disability.

As a primary care physician you are well aware of the demands placed on the healthcare industry with the rapidly aging population. The “baby boomers” are living longer and are focused on health, fitness and an active lifestyle. Although this is true to active lifestyle create incidence of musculoskeletal complaints and arthritis of large joints. The socioeconomic impact that the baby boomer population places on the field of medicine has created an unprecedented demand for alternatives for orthopedic and musculoskeletal injury, and degenerative disease. We saw this trend coming 20 years ago and prepared for it. Our organization has been preparing diligently to meet the demands that will be placed before us in dealing with patients with chronic musculoskeletal complaints. The primary care physician remains the portal of entry into the healthcare system and will need to gradually become more and more familiar with the methods and technical expertise of these new interventional orthopedic specialists. We are poised to provide additional educational services, or meet with your staff or provide postgraduate education to primary care physicians in regard to our science and technology we utilize.

### **HISTORY OF INTERVENTIONAL REGENERATIVE ORTHOPEDIC MEDICINE:**

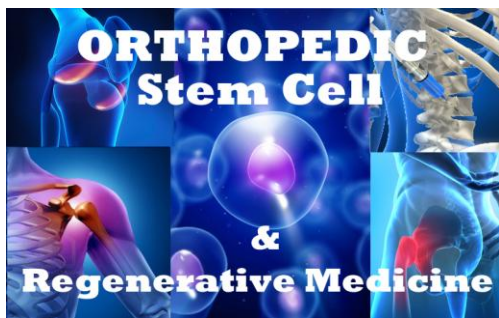
This discipline of interventional regenerative medicine has been in a state of evolution for a number of years. There are no residency programs or traditional medical training programs in this field to date. Currently, there are only two or three cell training programs worldwide. Fifty years ago the field was comprised of a handful of physicians who were considered “mavericks” using special injection techniques to cause the proliferation of collagen and connective tissues in ligaments and tendons. Physical Medicine and Rehabilitation physicians began to take an interest in these simple interventions and started conducting clinical trials and research in some of these earlier techniques. These early methods involved the use of hyperosmotic dextrose injections which caused osmotic cellular injury, thereby releasing tissue growth factors that stimulated fibroblast to produce collagen in tendon and ligament tissues. In 1993 we personally brought together a medical pathologist and a veterinarian institution to begin work on the use of platelet derived growth factors to induce tissue healing of tendons, ligaments and the annulus fibrosus in lumbar discs in animals.

We were utilizing plasmapheresis to obtain platelet concentrates. Others began to view this process as to cumbersome and developed simple centrifuge techniques, which were then adopted by physicians around the world. This ultimately spawned many companies which now make sell various Platelet Rich Plasma (PRP) centrifuge systems for this purpose. This was only the beginning some 20 years ago. With approximately 700 articles published over this period of time, 50% showing clinical efficacy and 50% showed no statistical difference from placebo to control groups, there continued to be numerous unanswered questions with the utilization of these early techniques. It was not until meta-analysis data became available from all of these studies

that we began to understand that there were specific laboratory preparations of Platelet Rich Plasma that were favored in specific conditions. In other words, you have to match the right protocol to the right condition.

Physicians with skills in ultrasonography began to implement precision injection techniques to target tissues with visual defects such as tendon tears and degenerative changes. With image guided injection techniques we began to see improved clinical outcomes. At the same time, various autologous stem cell therapies began to emerge providing physicians who possessed specialized skill and experience in these techniques more diverse choices of therapeutic intervention for specific disease entities began to emerge. Later we began to understand the importance of tissue engineering techniques and began to integrate the use of extracellular matrix proteins, connective tissue scaffolding techniques with other biologic interventions and stem cell. We began to realize that stem cell therapies were only a small component needed to heal various soft tissue pathologies. We spent years developing the laboratory techniques and exploring what other companies and laboratories had developed to be used in conjunction with our regenerative and biological interventions. We were later to learn that the protocol used with each disease state needs to be unique and well thought out to improve clinical outcomes. We also could not have accomplished what we have without the collaborative efforts of a physician and basic science Consortium. A group of like minded physicians with similar training and experience, came together 2 years ago and began to collaborate and share intellectual properties, techniques and methods and most importantly began to develop consensus about disease management. These collaborative efforts lead to our current “tissue engineering approach” and to our Interventional Regenerative Orthopedic Medicine Institutes.

### **THE MODERN IROM PRACTITIONER:**

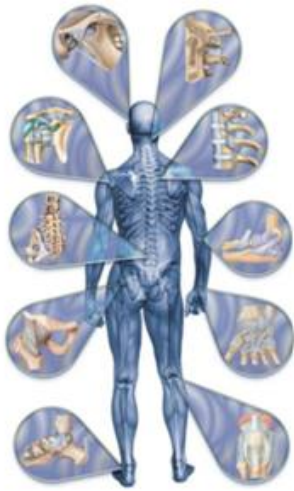

The modern orthopedic medicine practitioner is a physician who has diversified their skills. Physiatrists or doctors of physical medicine & rehabilitation with fellowship training in spine and interventional pain medicine have for the most part has been behind the development of this field. We are now seeing anesthesiology pain physicians, sports medicine physicians and orthopedic surgeons joining these efforts to advance this field. Interventional orthopedic practitioners utilize primarily “non-operative” orthopedic procedures in managing spine and joint conditions. These practitioners must devote years of training to master ultrasonography and integrate

diagnostic musculoskeletal ultrasonography and ultrasound guided procedures with the fluoroscopy techniques they have already mastered. They require advanced training and knowledge in orthopedics, biomechanics, sports medicine, rehabilitation, manual medicine and to some degree alternative medicine. They must understand how to read MRI’s and CT’s and integrate the physical assessment, ultrasonography examination with other diagnostic imaging to provide precision diagnosis. They require special training well beyond their fellowship training to develop an understanding of soft tissue injury, and degenerative disease of cartilage, ligaments, tendons, muscles, and connective tissues. They are also integrating their skills with peripheral entrapment neuropathies and other neurologic conditions.

Dr. Brown, our Washington and California based IROM physician has a unique background in that he began his career as a chiropractor and later worked extensively in chiropractic and osteopathic manual therapy, acupuncture dry needling, sports medicine, orthopedics and neurology. His extensive experience in ultrasonography, biomechanics and clinical orthopedic assessment is integrated with his alternative medicine background, providing patients a unique experience with his multidisciplinary approach and comprehensive evaluation process.





Patients who seek the care of these specialized physicians are often those who have spent months or years in conservative care which includes medication, physical therapy, chiropractic or osteopathic manual therapy, acupuncture, massage therapy and a host of other alternatives. They have failed pharmaceutical management, corticosteroid injections, and often surgical management. The IROM practitioner is an injection specialist, but typically does not emphasize the use of corticosteroid injections. These practitioners seek to utilize special technologies aimed at healing soft tissue, degenerative disease or injury. They also have to have a keen understanding of post procedural rehabilitation care and protocols. This saves time and money as well as the physical and emotional effects of chronic pain on an individual. The modern day orthopedic regenerative medicine specialist requires a different skill set than typical physical medicine physicians or sports medicine physicians and requires several additional years of hands-on advanced clinical training to add to their foundational subspecialty training.

### **WHAT CONDITIONS DOES AN INTERVENTIONAL ORTHOPEDIC PRACTITIONER TREAT?**

We specialize in orthopedic and musculoskeletal medicine. We deal with injuries, degenerative joint disease and difficulties involving:

- **Low back pain**
- **Neck and mid back pain**
- **Foot and ankle**
- **Lower extremity including knee and hip**
- **Shoulder**
- **Elbow, forearm, wrist and hand**
- **Biomechanical and gait analysis including fabrication of orthotics**
- **Peripheral entrapment neuropathies**
- **Myofascial pain syndromes**
- **Headaches**

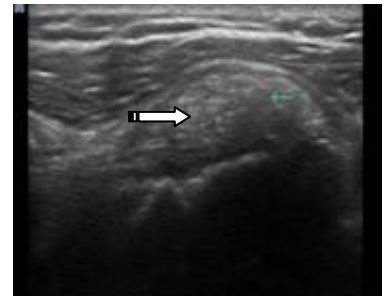
The area of orthopedics and musculoskeletal medicine is a vast subspecialty that requires knowledge of the musculoskeletal system including functional anatomy, biomechanics, orthopedic pathology involving muscles, tendons, ligaments, cartilage and bone disease. Most individuals do not appreciate the complexity of musculoskeletal medicine. We live in an area of a fitness boom which has reduced cardiovascular and other risk factors but has also led to issues of cumulative joint trauma, sports and recreational injuries leading to progressive degenerative disease. Obesity and sedentary lifestyles have also had a toll on these individual's spine and joints. Regardless of the cause, we have an aging "baby boomer" population that is going to have a significant socioeconomic impact on the medical system that is providing care for these musculoskeletal and orthopedic conditions.

We believe that the advanced Interventional Regenerative Orthopedic Medicine practitioner is well positioned to intervene for these patients when there are complex clinical presentations and oftentimes multiple joint involvement. The IROM practitioner needs to be willing to spend often times considerable time with an individual patient dealing with the complexity of clinical presentation. The typical 10-15 minute office visit is not possible with this patient population. You do not have the luxury of dealing with one problem at that time because insurance reimbursement does not allow otherwise. It is common placed to spend an hour or more with each patient. The complexity of these clinical presentations and the complexity of intervention techniques requires this devoted time and attention to detail. This topic is so vast we could write a text book. We felt that the best way to communicate to a physician to demonstrate our unique approaches would be to present a series of these cases to allow one to develop an understanding of how a IROM practitioner would handle specific clinical entities and to contrast the differences between conventional approaches in sports medicine and physical medicine & rehabilitation to the IROM approach.

## CASE STUDIES:

### Case #1: The Painful Shoulder

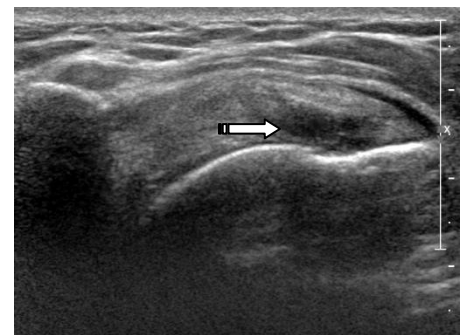
A 52-year-old Caucasian female is seen with severe left shoulder pain. Pain progressively worsened and became so severe she was immobilizing the shoulder in a sling to remain comfortable. On physical exam she had exquisite tenderness over the anterior shoulder over the subscapularis tendon. On ultrasound examination she had a large calcific density expanding the subscapularis tendon and on ultrasound exam there was a dynamic impingement of the tendon under the coracoid process during internal rotation of the shoulder. She had associated severe subcoracoid bursitis. She had failed all conservative management. Atypical corticosteroid injection may provide immediate relief but without dealing with the tendon pathology. The patient could only expect a short period of transient symptomatic improvement before symptoms recurred. Targeting the subacromial bursa, which would typically be the most common approach would also be inappropriate since it would target the wrong bursa based on ultrasonography examination. It is the subcoracoid bursa. That would be the target for corticosteroid injection to provide a period of transient symptomatic relief. Under ultrasound guidance, the subcoracoid bursa was infiltrated with local anesthetic and corticosteroid. This in fact did provide immediate symptomatic relief allowing us some time to intervene with the significant rotator cuff pathology.



Following the corticosteroid injection the patient was scheduled back for re-evaluation and under ultrasound guidance the large calcific tendinosis was fenestrated with a needle under local anesthetic and an ultrasound guided percutaneous decalcification procedure was carried out followed by intratendinous injection of platelet releasate. Platelet releasate is a special laboratory process where by autologous platelet rich plasma is prepared and then the platelets are activated to release alpha granules into autologous plasma. This provides a autologous plasma that is rich in platelet derived growth factors rather than a platelet rich plasma prep. There are certain times when this platelet preparation is preferred over platelet rich plasma. Intratendinous infiltrations of growth factors, platelet releasate and local anesthetic completely resolved the large calcification and the patient has been asymptomatic for 24 months. It should be pointed out that the cost of care of months and months of physical therapy, conservative care, medications, MRI studies, and multiple subspecialty consultations could all be avoided with early intervention. Two simple interventions directed to a precision diagnosis resolved this patient's problem and she is no longer seeking care within the system. This results in significant costs savings.

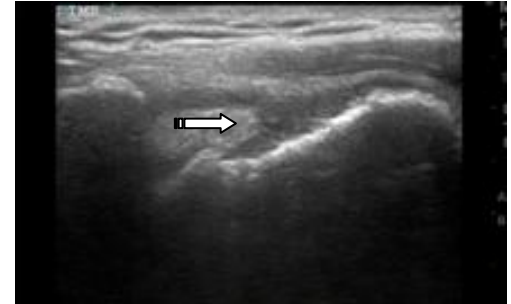
### Case #2: The Painful Shoulder

46-year-old Caucasian male presents with a year and a half of persistent subacromial shoulder pain unresponsive to conservative treatment. MRI demonstrates large partial-thickness tear of the supraspinatus tendon. Patient desires non-operative management if possible, and is seen for interventional orthopedic regenerative medicine consultation. This patient has a supraspinatus tendon tear on ultrasound with tissue defect. Although the use of platelet Rich plasma injections have been commonplace in sports medicine and physical medicine rehabilitation practitioners offices, this type of tear does not heal well with simple platelet rich plasma injections. Repeated PRP injections would lead to escalating costs of care, which is typically paid out-of-pocket by the patient. An orthopedic surgical consultation and surgical repair of the rotator cuff leads to protracted recovery time and significant expense. The IROM approach was to utilize a proprietary autologous collagen extracellular matrix graft in conjunction with other biologic, growth factor, and, cellular therapies including stem cell injected within the defect. The shoulder will require some period of immobilization, but postprocedural pain recovery occurs in days not months. This patient went on to have rapid resolution of shoulder pain and is now back in a gym based exercise program and recreational activity. This was done with minimal downtime and a cost savings since we were able to avoid surgical repair.



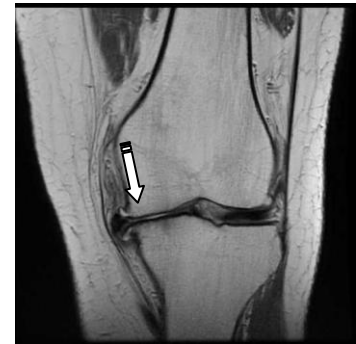### Case #3: The Painful Shoulder

46-year-old Caucasian male who has been participating in gym based weight lifting exercises for years presents with two year history of chronic shoulder pain. He has failed conservative measures. He has not had an MRI study. He was seen for interventional orthopedic consultation. Ultrasound examination noted to the right demonstrated full-thickness tear with full retraction of the supraspinatus tendon. The tissue defect was much too large to consider regenerative injection therapies. MRI was ordered and the patient was referred to orthopedic surgery for surgical rotator cuff repair. It is important to emphasize that there are certain rotator cuff pathologies that are conducive to regenerative injection therapies and others that are better suited for orthopedic surgery. Interventional regenerative orthopedic medicine has its place in providing non-operative orthopedic intervention, but a multidisciplinary approach is always necessary.



### Case #4: The Osteoarthritic Knee

59-year-old Caucasian female correction officer works in a prison. She climbs stairs through the day and has a 10 year progressive worsening of knee pain and functional disability. Patient had MRI demonstrating advanced arthropathy with stage IV chondrosis and tricompartmental osteoarthritis. She was offered a total joint arthroplasty. She is 59 and wants to be able to retire from the prison system before she considers a total joint arthroplasty. She also wants to avoid the significant time off work that a total joint arthroplasty would require. She is looking for non-operative options for management of pain and functional disability. MRI of the knee demonstrates full thickness cartilage loss, a peripheral meniscus extrusion with tear of the medial meniscus and advanced degeneration of the posterior horn of the medial meniscus. Bone marrow edema was present under the cartilage defects under the medial femoral condyle on T2 imaging not shown. A decision was made to utilize a specific type of stem cell that was placed intraosseous within the medial femoral condyle under fluoroscopic guidance. In addition, a proprietary extracellular matrix scaffolding graft was utilized within the meniscotibial ligaments and placed around the articular capsule and medial meniscus in conjunction with injection of other biological interventions, growth factors, and a specific type of PRP containing alpha-2-macroglobulin. This was all done as a same day procedure in a patient who was becoming functionally impaired and hardly able to get around work. 3 months postprocedure. The patient reports no significant pain in her knee. She only has occasional discomfort and is able to negotiate stairs and work in her usual and customary work duties without significant difficulties. She still has some residual pain when performing certain physical activities, but overall she is markedly better. The patient may require occasional intervention but it is felt we can delay total joint arthroplasty and keep the patient comfortable until she retires. There are huge implications in this case. She is 59 years of age. When you have a knee replacement you want to have only one. Since total joint arthroplasty is not a permanent correction and has a specific life expectancy to the procedure a revision surgery would more than likely be something. This patient would be facing in the future. Revision surgeries are more difficult and can have more associated morbidity. Having an option for nonoperative management that can manage the arthritic disease and maintain comfort and reduce functional disability could potentially delay this patient from having an early knee replacement surgery. The patient has been able to continue her appointment and was unlikely will be able to continue to do so with minimal interventions allowing her to retire with full benefits.

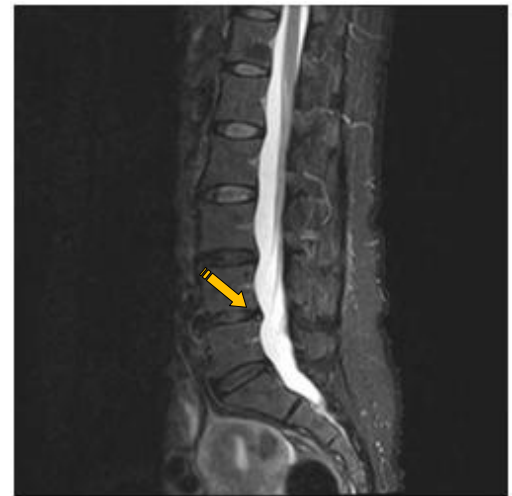

When we will utilizing simple stem cell injection procedures we noted in consistencies in clinical outcomes in patients with stage IV osteoarthritis such as this patient demonstrated. We explored numerous stem cell interventions and there was always an unacceptable percentage of patients who did not respond or partially responded. For years we worked on developing protocols to manage more significant arthritic disease in the knee. We were eventually able to develop a tissue engineering approach utilizing proprietary techniques that incorporate extracellular matrix scaffolding grafts, various biological interventions including cellular therapies, growth factors, and a specific isolation of autologous plasma proteins. Once we had this specific biologic intervention.

We also had to learn how to use it. We have finally developed a protocol that we believe has consistently made a significant difference in patients with stage IV osteoarthritis. Now that we have advanced this technique to this point. We plan to begin conducting multicenter clinical trials in 2016. This has taken painstaking efforts and a collaboration with multiple physicians in basic research scientist to accomplish what we have today.

#### **Case #5: Chronic Low Back Pain**

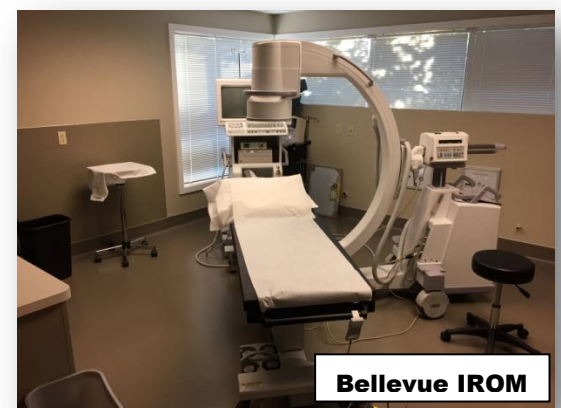A 46 year old female, well known author and celebrity has had long standing and progressive worsening chronic lower back pain. The patient has failed all conservative management. She has had pain overlying the lumbosacral spine and the left sacroiliac joint. She has had countless physical therapists and manual therapy practitioners directing manual therapy to what was thought to be chronic SI joint pain for years. Patient now unable to participate in her recreational activities of interest and is having trouble doing a gym based exercise program. We suspected that the sacroiliac joint was not the source of pain and that she was experiencing a “pseudo-sacroiliac” joint pain phenomenon caused by a tear in her L4-L5 disc. We performed an analgesic discography of L4-L5 disc which demonstrated a symptomatic annular tear. Patient’s left SI joint symptoms resolved completely during the anesthetic phase of the L4-L5 intradiscal injection. The patient underwent an intradiscal injection procedure developed by our research team. This involved the injection of a proprietary collagen and extracellular matrix scaffolding as well as a modified fibrin glue as well as a proprietary stem cell injection prep with necessary, growth factors and peptides. The patient had normal post-procedural recovery period, and at four weeks the patient was experiencing significant improvement. At eight weeks patient had almost complete resolution of low back pain except for residual pain overlying the right sacroiliac joint. A PRP injection was performed directed to the right SI joint which resolved the SI joint symptoms. Patient is now in a gym based exercise program and participating in her recreational activities she enjoys. Patient is now reporting this has “changed my life.”



This patient had already failed chiropractic, osteopathic, and physical therapy treatment. Pain medications and pharmaceutical pain management did not keep the patient’s symptoms under control. Corticosteroid injections would have been of no benefit. Since the patient’s pain was secondary to discogenic pain with a partial contribution from the sacroiliac joint interventions such as radiofrequency neural ablation procedures would have been ineffective. What choice would this patient have had without this innovative approach? The criticism would be that we are utilizing investigational techniques. All of the techniques that we use are for the most part “investigational.” Despite the fact PRP injections directed to arthritic joints, tendons and ligaments are used by thousands of physicians worldwide, this technique is still considered “investigational.” The critical factor is that we began with a persistent diagnosis and an in-depth understanding of the pathophysiology involved in the patient’s clinical presentation. We select what we feel is the best approach that science and technology has to offer. This requires that we remain up to date with the constantly changing science and technology in this field. We accomplish this by tiredness efforts of multiple physicians within the IROM Consortium.

#### **IROM INSTUTUTE**

Currently, we have six institutes scattered around the United States. These locations include Texas, Pennsylvania, Ohio, Florida, California, and Bellevue, Washington. These facilities are equipped with a full fluoroscopy suite. This prevents us from having to go to the OR and outpatient surgical centers for procedures thus significantly reducing the expense for our patients. We are also equipped with an ultrasound diagnostic and procedure suite, a stem



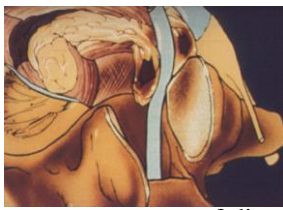cell and biologic lab, and a rehabilitation facility for spine and extremity rehab. We are able to perform all of our procedures same day with all cell isolation and laboratory preparation performed within the institute.

We have affiliated with our institution engineers, PhD stem cell scientists and stem cell biologists assisting in our research and development, bench research, and providing assistance in clinical trials. Our engineering team provides a means for us to develop our instrumentation and proprietary technology for which we are currently working on for 510K FDA approval.



### **CHRONIC NECK AND BACK PAIN: OUR APPROACH**

Our physicians have abandoned many of the traditional approaches of the pain medicine physicians. We believe that repeated corticosteroid injections, repeated epidural blocks, etc. provide little long-term benefit. We limit the use of corticosteroid epidural injections. We also believe that traditional approaches involving radiofrequency ablation procedures provide at best transient symptomatic relief until medial branch nerves regenerate when the procedures then have to be repeated again and again. Chronic opioid management has been a dismal failure in this country. We also feel strongly that interventional pain physicians that utilize a “let’s try this” approach with injection procedures is inappropriate. We strive to provide “precision diagnosis and definitive therapeutics.” In order to accomplish a precision diagnosis with the chronic back or neck pain patient a significant time is spent with the patient and a detailed evaluation which may include local anesthetic pain mapping procedure and advanced sequential diagnostic **testing that is done on the same date of service**. Commonly, patients with back pain have multiple pain generators. This increases the complexity of the clinical presentation. We try to sort out all potential pain generators and develop comprehensive interventional treatment plans directed to **all of the pain generators**. We also have a comprehensive understanding of spine rehabilitation protocols, and integrate our understanding of manual therapy, alternative therapies and physical rehabilitation with our interventions.

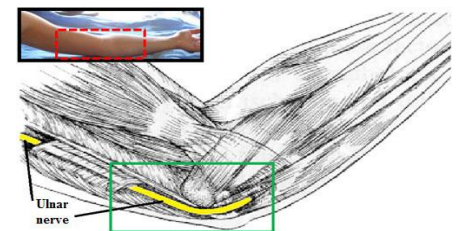


Many physicians in primary care may not realize how many alternatives are currently available for even a simple clinical presentation such as a herniated disc. We have taken a surgical approach far too often in the US, while the rest of the world has been developing more reasonable and minimally invasive procedures that can deal with herniated disc patients that are resulting in outcome similar to surgery. We have explored these alternative methods and utilize them on a regular basis. There are numerous types of disc protrusions and herniations. Treatment needs to take into consideration. A careful diagnostic categorization process and to take under consideration a number of pathophysiologic processes that may be occurring. We undertake painstaking efforts to use specific categorization processing to develop the correct treatment protocol.

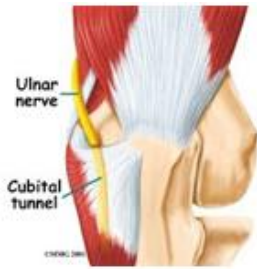We believe the key to success is again a **precision diagnosis**. The procedures provided need to be done in appropriately selected patients. We have worked extremely hard in our institutes to develop consensus guidelines that govern the manner in which we select patients for given procedures based on collective clinical outcome data and experience. We encourage all primary care physicians to feel free to contact us to discuss difficult cases since the approach must be customized for each patient’s presentation.

### **NERVE ENTRAPMENT SYNDROMES?**

The interventional orthopedic practitioner also possesses specialized skills in dealing with countless nerve entrapment syndromes. With years of study utilizing ultrasound diagnostic evaluation of nerves and specialized ultrasound-guided procedures directed to nerve entrapment syndromes, the interventional practitioner can often help people with intractable nerve entrapment pain that has been unresponsive to other conservative care or even surgery. Pioneers from Japan and other parts of the







world have integrated the use of advanced ultrasound procedures, regenerative medicine principles and non-surgical methods to decompress the nerve. We have adopted and learned from these providers and utilize these methods in our centers. For example, a patient with ulnar neuropathy or cubital tunnel syndrome may experience ongoing ulnar distribution symptoms of numbness, tingling and pain. Typically, these patients are referred for electrodiagnostic testing followed by referral to surgery for ulnar nerve transposition surgery.

It is our opinion that neural sonography (ultrasonography of the nerve and the nerve pathway) should be performed in addition to electrophysiologic testing. Oftentimes, ultrasonography examination of the region of nerve entrapment reveals certain findings and clues to pathology that is not provided by conventional electrodiagnostic testing. Ultrasonography can reveal information about the location and cause of a specific entrapment neuropathy. Not only can provide information on the possible etiology of the entrapment neuropathy but also may provide information in regards to the degree and severity of nerve dysfunction and pathology.

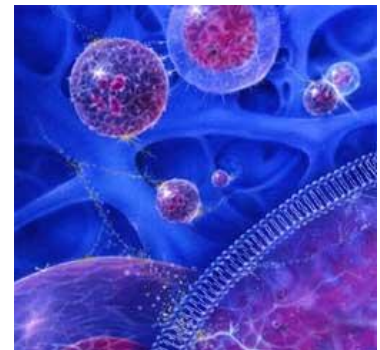
For example, a patient may have presentation of ulnar neuropathy at the elbow after a traumatic injury but present on ultrasound with intraneural fibrosis. This patient will do poorly with ulnar nerve transposition procedure. Other patients may demonstrate signs of compressive neuropathy with increased neural fascicle size secondary to connective tissue entrapment. In these patients a special procedure performed under ultrasound guidance is utilized to track a needle next to the nerve and use a connective tissue neural fascial hydrodistention of the tissues away from the nerve often relieving compression and returning nerve fascicle size and function to normal. This can be performed without the use of decompression surgical procedures or nerve transposition. We feel the simple procedures should be attempted prior to consideration of surgical intervention. For those who want additional information, please visit the “Patient Education” section of our website at [www.michaelnbrownmd.com](http://www.michaelnbrownmd.com) for the article entitled “Neural Fascial Hydrodistention”. There are also numerous other articles available for download.

#### **ARE THESE SERVICES COVERED BY INSURANCE?**

Unfortunately, the majority of our procedures are not covered by insurance. We have adopted a fee for service practice model. We have worked extremely hard to develop our laboratory processing, procedures, and methods to bring the cost of our care to a minimum so that individuals are paying reasonable rates for even our most advanced cellular based technologies. We have a host of choices, alternatives and procedures and take pride in trying to avoid unnecessary expense. We offer each patient the technology that is the most appropriate method of treatment for the best possible clinical outcome.

#### **BREAKTHROUGHS IN REGENERATIVE MEDICINE TECHNOLOGY AT OUR CENTERS:**

Over the course of the last 5 years the physicians within our organization have been working diligently with PhD basic scientists and engineers to develop new regenerative technologies, laboratory preparation procedures, and a host of techniques and protocols that we have been testing over throughout this time period. Members of our team have obtained FDA approval for some of their innovations. We are working on more at present date. We have, proprietary laboratory processing techniques utilized for innovative stem cell isolation.



Our stem cell technologies again are carefully integrated with other regenerative and dorsal biological interventions to improve clinical outcomes. We are currently utilizing proprietary protocols and techniques to manage discogenic back pain as previously stated.

#### **IN SUMMARY:**

IROM practitioners is a rapidly emerging subspecialty field in medicine that may provide the primary care physician another option for referral to subspecialty consultation in selected patients. This type of service is typically utilized for patients who are not responding to conventional/conservative means and is seeking

nonsurgical intervention. These patients often find themselves frustrated and living with chronic pain seeking alternatives for treatment. We hope this information has been helpful for your review. If there are any questions you may have or if you would like to hear from us for further information please do not hesitate to contact us.

**REFERENCES:**

1. Jensen KT, Rabago DP, Best TM, Patterson JJ, Vanderby R, Jr. Response of knee ligaments to prolotherapy in a rat injury model. *The American journal of sports medicine*. 2008;36(7):1347-1357.
2. Andrianakos A, Kontellis L, Karamitson D, al. E. Prevalence of symptomatic knee, hand and hip osteoarthritis in Greece. The ESORDIG study. . *J. Rheumatol*. 2006;33:2/5/07-2513.
3. Dagenais S, Garbendian S, Wal E. Systematic review of prevalence of radiographic primary hip osteoarthritis. *Clin Orthop Related Res*. . 2009;246:6623-6637.
4. Gunther K, Puhl W, Brenner H, Sturmer T. Clinical epidemiology of hip and knee joint arthrosis an overview of the results of the "Ulm osteoarthrosis study". . *Z Rheumatol* 2009;61:244-249.
5. Cross M, Hoy D, Nolte S, Ackerman I, al. E. The global burden of hip and knee osteoarthritis: estimates from the Global Burden of Disease 2010 study *Ann Rheum Dis* doi:10.1136/annrheumdis-2013-204763.
6. Iorio R, Kurtz S, Lau E. *The Journal of Arthroplasty* Vol. 25 No. 8 2010.
7. Smith M, Davis M, Stano M, Whedon J. Aging Baby Boomers and the Rising Cost of Chronic Back Pain: Secular Trend Analysis of Longitudinal Medical Expenditures Panel Survey Data for Years 2000 to 2007. . *JMPT*. 2013;36(1):2-11.